



PATIENT

Milo Borlestean

SPECIES

Feline

BREED

DSH

SEX

Male Neutered

AGE

2 years

WEIGHT

12.6lbs

INTERPRETED BY

Maggie Machen Lamy,
DVM, DACVIM
(Cardiology)

IMAGING PERFORMED BY

Jacque Pankatz,
DVM

HOSPITAL NAME

Mountain Vista
Veterinary Hospital

REFERRING VET

Dr. Pankatz

INVOICE

26617

DATE

9/29/22

PRESENTING CLINICAL SIGNS

History: New grade 2/6 heart murmur. Asymptomatic.

ECHOCARDIOGRAM FINDINGS

2D, m-mode, color flow and doppler imaging is available. The left ventricular wall is irregular with borderline dimensions overall. There is a hyperechoic endocardium consistent with fibrosis. The papillary muscles are mildly remodeled and hyperechoic. The left atrium is normal in size. The right atrium is normal in size. The right ventricle appears normal. The mitral valve is normal in structure and mobility. No MR or TR. Blood flow through both the LVOT and RVOT is normal in velocity. No pleural or pericardial effusion seen. No obvious cardiac tumors.

CARDIAC CHART

FELINE CARDIAC PARAMETERS	BODY WEIGHT (kg)	HR (BPM)	IVSd (cm) (Moise, Pipers)	LVIDd (cm) (Moise, Pipers)	LWVd (cm) (Moise, Pipers)	FS (%)	EF (%)
NORMAL PARAMETER	-----	150-240	0.35-0.55	<2 (mean 1.5)	3.5-0.55	35-67	80-100
PATIENT	5.7	NM	0.55	1.4	0.55	53	87
FELINE CARDIAC PARAMETERS	LA/AO (Boon)	LA/AO HEART BASE (Swe) (Abbott)	LA 2D short axis Base view (cm) (Abbott)		LVOT VEL (m/s)	RVOT VEL (m/s)	E max (m/s)
NORMAL	<1.5	<1.3	<1.2		<1.6	<1.3	<0.9
PATIENT	1.4	1.1	1.1		1.5	0.8	NM

**Note: All measurements based upon multi-modal images and methods. An average value is reported.
Adapted from June Boon, Veterinary Echocardiography, 1998
Abbott J & MacLean H JVIM 2006;20: 111-119, Moise et al. Am J Vet Res 47:1476, 1986. Pipers et al. Am J Vet Res 40:882, 1979.*

INTERPRETATION OF THE FINDINGS & FURTHER RECOMMENDATIONS

Borderline LV dimensions are noted, which may be indicative of early hypertrophic disease or may simply represent a normal variant. Rule out hypertension or hyperthyroidism as possible contributing factors. Regardless, the LA remains normal which would indicate clinical stability. Serial echocardiography will be necessary to determine progression and clinical significance. Additionally, no definitive cause is identified for the murmur in this study, making it likely benign.

Given a normal LA dimension, no medications are indicated.

Anesthetic risk is mild, however any cat with this degree of fibrosis and diastolic dysfunction will be at risk for iatrogenic IV fluid overload should they be needed in the future. No obvious contraindication for steroid use at this time.

Monitor for any development of clinical signs, including labored breathing or signs of a blood clot (paralysis, neurologic change).

A recheck echocardiogram is recommended in 6-12 months to screen for any evidence of progression.



PATIENT

Milo Borlestean

SPECIES

Feline

BREED

DSH

SEX

Male Neutered

AGE

2 years

WEIGHT

12.6lbs

INTERPRETED BY

Maggie Machen Lamy,
DVM, DACVIM
(Cardiology)

**IMAGING
PERFORMED BY**

Jacque Pankatz,
DVM

HOSPITAL NAME

Mountain Vista
Veterinary Hospital

REFERRING VET

Dr. Pankatz

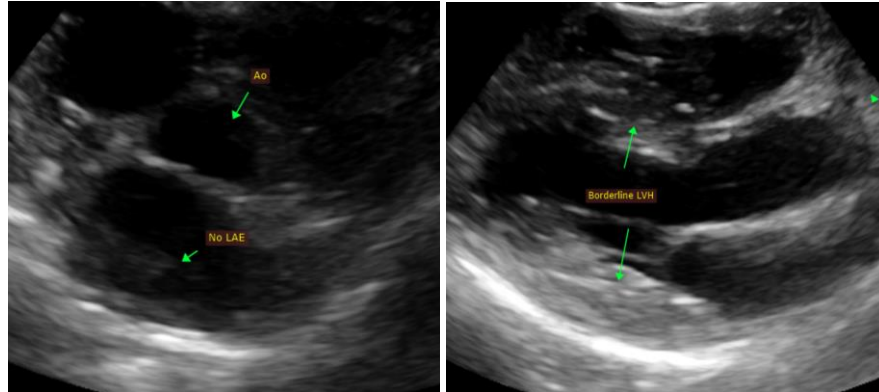
INVOICE

26617

DATE

9/29/22

IMAGES



The information and recommendations provided are based on the images presented by the referring veterinarian. No evaluation can be communicated regarding pathology that was not visible in the image/video clips provided.

Thank you for this referral. This report was generated using transcription software, and minor dictation errors may be present. If the clinical or image interpretation does not parallel your findings or if I can be of any further assistance, please contact me.

Maggie Machen Lamy, DVM
Diplomate of the American College of Veterinary Internal Medicine (Cardiology)
info@sonopath.com